

ARTICLE

Clinical and molecular genetics of patients with the Carney–Stratakis syndrome and germline mutations of the genes coding for the succinate dehydrogenase subunits *SDHB*, *SDHC*, and *SDHD*

Barbara Pasini^{1,16}, Sarah R McWhinney^{2,16}, Thalia Bei³, Ludmila Matyakhina³, Sotirios Stergiopoulos³, Michael Muchow³, Sosipatros A Boikos³, Barbara Ferrando¹, Karel Pacak⁴, Guillaume Assie^{5,14}, Eric Baudin⁶, Agnes Chompret⁷, Jay W Ellison⁸, Jean-Jacques Briere^{9,10}, Pierre Rustin^{9,10}, Anne-Paule Gimenez-Roqueplo^{11,12,13,16}, Charis Eng^{2,14,16}, J Aidan Carney^{15,16} and Constantine A Stratakis^{*,3,16}

¹Department of Genetics, Biology and Biochemistry, University of Torino, Turin, Italy; ²Department of Molecular Genetics, The Ohio State University, Columbus, OH, USA; ³Section on Endocrinology and Genetics, Pediatric Endocrinology Training Program, Developmental Endocrinology Branch, National Institutes of Health, Bethesda, MD, USA; ⁴Reproductive Biology and Medicine Branch, National Institute of Child Health and Human Development, National Institutes of Health, Bethesda, MD, USA; ⁵INSERM U567, Institut Cochin, Département d'Endocrinologie, Paris, France; ⁶Cancerologie Endocrinienne, Institut Gustave Roussy, Villejuif, France; ⁷Oncogenetique, Institut Gustave Roussy, Villejuif, France; ⁸Department of Medical Genetics, Mayo Clinic, Rochester, MN, USA; ⁹INSERM, U676, Paris, France; ¹⁰Faculté de Médecine Denis Diderot, Université Paris 7, IFR02, Paris, France; ¹¹Department of Genetics, Assistance Publique-Hopitaux de Paris, Hopital Européen Georges Pompidou, Paris, France; ¹²Faculté de Médecine, Université Paris-Descartes, Paris, France; ¹³INSERM, U772, Collège de France, Paris, France; ¹⁴Genomic Medicine Institute, Lerner Research Institute and Taussig Cancer Center, Cleveland Clinic Foundation, Cleveland, OH, USA; ¹⁵Department of Laboratory Medicine and Pathology, Mayo Clinic, Rochester, MN, USA

Gastrointestinal stromal tumors (GISTs) may be caused by germline mutations of the *KIT* and platelet-derived growth factor receptor- α (*PDGFRA*) genes and treated by Imatinib mesylate (STI571) or other protein tyrosine kinase inhibitors. However, not all GISTs harbor these genetic defects and several do not respond to STI571 suggesting that other molecular mechanisms may be implicated in GIST pathogenesis. In a subset of patients with GISTs, the lesions are associated with paragangliomas; the condition is familial and transmitted as an autosomal-dominant trait. We investigated 11 patients with the dyad of 'paraganglioma and gastric stromal sarcoma'; in eight (from seven unrelated families), the GISTs were caused by germline mutations of the genes encoding subunits B, C, or D (the *SDHB*, *SDHC* and *SDHD* genes, respectively). In this report, we present the molecular effects of these mutations on these genes and the clinical information on the patients. We conclude that succinate dehydrogenase deficiency may be the

*Correspondence: Dr CA Stratakis, Section on Endocrinology and Genetics (SEGEN), Pediatric Endocrinology Training Program, DEB, NICHD, NIH, Building 10, CRC, Room 1-3330, 10 Center Dr., MSC1103, Bethesda, MA 20892, USA.
Tel: + 301 496 4686/496 6683; Fax: +301 301 402 0574/480 0378,
E-mail: stratakac@mail.nih.gov

From the Carney Triad and Carney-Stratakis Dyad Consortium.

¹⁶Drs Pasini and McWhinney have contributed equally to this work and they are sharing first authorship of this work; Drs Gimenez-Roqueplo, Eng, Carney and Stratakis have also contributed equally to this work and are sharing the senior authorship.

Received 8 May 2007; revised 16 June 2007; accepted 19 June 2007; published online 1 August 2007

cause of a subgroup of GISTs and this offers a therapeutic target for GISTs that may not respond to STI571 and its analogs.*European Journal of Human Genetics* (2008) **16**, 79–88; doi:10.1038/sj.ejhg.5201904; published online 1 August 2007**Keywords:** gastrointestinal stromal tumors; succinate dehydrogenase subunits B, C and D; paraganglioma; tumor suppressor gene**Introduction**

Gastrointestinal stromal tumors (GIST) may be sporadic or inherited in an autosomal-dominant manner either alone or as a component of a syndrome associated with other manifestations or predisposing to the development of multiple tumors.¹ Recently, we described 12 young patients (seven male and five female with an average age of 23 years) from five unrelated families who had both GIST and paraganglioma; the tumors were inherited in an apparently autosomal-dominant manner, with incomplete penetrance.² GISTs in these patients were multifocal and paragangliomas multicentric, supporting a genetic link between the two lesions. The condition has been referred to as the dyad of 'paraganglioma and gastric stromal sarcoma' or the 'Carney–Stratakis syndrome' or Carney–Stratakis dyad.³

Germline mutations of the genes encoding succinate dehydrogenase subunits B, C and D (*SDHB*, *SDHC* and *SDHD*) had been described in inherited paraganglioma and pheochromocytoma^{4–8} but not in familial GISTs, until patients with the dyad were studied.⁹ In this report, we

describe the molecular and clinical effects of germline *SDHB*, *SDHC* and *SDHD* mutations in patients with the dyad and their tumors. Allelic losses around the *SDHB* and *SDHC* chromosomal loci were found in GISTs from these patients, pointing to a tumor-suppressor function of the succinate dehydrogenase subunits. These tumors did not exhibit the *KIT* or platelet-derived growth factor receptor- α (*PDGFRA*) gene mutations associated with GISTs and related lesions^{10–12} that are responsive to Imatinib mesylate (STI571) and its analogs.

Methods**Clinical studies and tissue samples**

The Institutional Review Boards of the participating institutions have approved the DNA and other studies of this investigation. Families with the dyad have been described by Carney and Stratakis² (Table 1). All patients had GIST or paraganglioma diagnosed by standard clinical and pathological criteria. Blood and tissue samples were collected from patients after informed consent, as

Table 1 Clinical and molecular genetics of patients with the dyad of 'paraganglioma and gastric stromal sarcoma'

Family/patient	Sex	Age ^a	Clinical manifestations; family Hx	Gene	Mutation
1/1. CTRS35	M	37	GIST; mother with pheochromocytoma	<i>SDHB</i>	IVS1+1G>T
2. CTR02 ^b					
2/2. PGL146001	M	12	PGL; one of twin brothers	<i>SDHB</i>	IVS4+1G>C
2/3. PGL146002	M	12	GIST; one of twin brothers	<i>SDHB</i>	IVS4+1G>C
3/4. B8893/T8231	F	26	GIST; multiple PGLs; father with mutation died of lung cancer at the age of 75	<i>SDHB</i>	c.45_46insCC
4/5. PGL214	F	29	GIST; PGL; unknown family Hx	<i>SDHC</i>	c.43C>T
5/6. CTRS8	F	20	GIST; PGL; mother is an unaffected carrier of the same mutation	<i>SDHC</i>	IVS5+1G>A
6/7. SDH9/04:MB 00205	M	19	GIST; multiple PGLs; pheochromocytoma; unknown family Hx	<i>SDHD</i>	c.57delG
7/8.CTRS20 ^c	M	9	GIST; multiple PGLs; mother with PGL	<i>SDHB</i>	Large deletion
8. CTRS1/3 ^c					
8/9. CTRS.1	F	20	Multiple PGLs; sister of CTRS.3		None ^d
8/10. CTRS.3	M	15	GIST; multiple PGLs		None ^d
9/11. CTRS18 ^c	M	19	GIST; multiple PGLs; two brothers with PGLs		None ^d

F, female; GIST, gastrointestinal stromal tumor; Hx, history; M, male; PGL, paraganglioma.

^aThis is the age at the time of presentation.

^bFamily CTR02 has been reported by Boccon-Gibod *et al*¹⁷.

^cKindreds CTRS20, CTRS1/3 and CTRS18 have been reported by Carney and Stratakis²; they are individual IV.4 in family 4, IV.1 and IV.4 in family 1, and III.2 in family 3, respectively.

^dNo mutations or large deletions were identified in the coding regions of the *SDHA*, *SDHB*, *SDHC* and *SDHD* genes.

described elsewhere.¹³ When possible, tissue was collected at surgery and processed for routine histopathology and immunohistochemistry following formalin fixation and paraffin embedment; additional fragments were frozen at -70°C . The antibodies for c-KIT, actin, desmin and vimentin were used at dilutions 1/1000, 1/1000, 1/200 and 1/500, respectively, and were obtained from DAKO (Carpinteria, CA, USA); the antibody for CD34 was used at a dilution of 1/100 and was obtained from BD Biosciences (San Jose, CA, USA); and the antibody for chromogranin A was diluted at 1/500 and was obtained from Chemicon (Temecula, CA, USA); for all the detection system was polymer based.

DNA was extracted from blood, frozen and archived tissue samples or cell lines using standard methods (Qiagen, Valencia, CA, USA). Tumor samples were micro-dissected from associated normal tissues.

Sequencing and allelic heterozygosity analysis

Mutation analysis for exons, exon–intron boundaries and flanking intronic regions was performed for the *KIT*, *SDHA*, *SDHB*, *SDHC*, *SDHD* and *PDGFRA* genes; polymerase chain reaction (PCR) was performed using Qiagen HotStarTaq kit (Qiagen) and primers that have been described elsewhere.^{5,6,8–12,14,15} An aliquot of the PCR product was purified with exonuclease I/shrimp alkaline phosphatase treatment (New England Biolabs, Beverly, MA, USA/USB Corporation, Cleveland, OH, USA). The purified amplicons were directly sequenced using Big-Dye Terminator v. 20 Cycle Sequencing kit (Applied Biosystems, Foster City, CA, USA) and analyzed on an ABI 3730 DNA analyzer (Applied Biosystems). Cell lines, blood cells or frozen tumor material were used for total RNA extraction, complementary DNA (cDNA) synthesis by reverse transcriptase PCR and sequencing, using appropriate transcribed sequence-based primers.

Tumor and DNA from other samples were also subjected to loss-of-heterozygosity (LOH) analysis using markers surrounding the genes in which mutations were identified (*SDHB* and *SDHC*, see below). Markers were selected using NCBI MapViewer35 (<http://www.ncbi.nlm.nih.gov/mapview/>); for each gene, at least 10 informative sequences were selected for heterozygosity studies, as described previously.¹³

For paternity and/or homozygosity testing (the latter for the twin brothers of family CTR02, see below), seven fluorescent polymorphic microsatellite markers located in three different chromosomes were used: they included *D1S159S*, *D1S2624*, *D11S934*, *D11S968*, *D14S264*, *D14S283* and *D14S990*, which were amplified and run using standard procedures.

All sequence variants that were identified in the study patients were also searched for in more than 100 ethnically matched-control DNA samples. The mutations we report were not found in any of the control samples; numerous polymorphisms were identified in the samples of the study

patients for all six genes that, however, were also present in the control samples (data not shown).

Search for microdeletions of *SDHB*, *SDHC* and *SDHD* and other loci

Tumor DNA was hybridized to Illumina (Illumina Inc., San Diego, CA, USA) HumanHap300-Duo Genotyping Bead-Chips, according to the manufacturer's protocol (www.illumina.com). Data analysis was performed using Illumina software BeadStudio (version 2) and R version 2.3 (R: A Language and Environment for Statistical Computing, R Foundation for Statistical Computing, Vienna, Austria) (data not shown). For the single patient in whom *SDHB* was deleted (CTRS20; Table 1), confirmation of the hemizygous deletion was performed with semi-quantitative duplex PCR of each *SDHB* exon compared to the housekeeping *GAPDH* exon 8 gene sequence using a method that we have reported elsewhere.¹⁶ For the experiments reported here, 20 ng of genomic DNA was used as template for each semi-quantitative PCR reaction with primers flanking each *SDHB* exon and those of *GAPDH* exon 8 (Table 2) using Qiagen HotStartTaq kit (Qiagen) and 30 cycles with an annealing temperature of 55°C .

Results

Germline and tumor DNA studies

We accrued a total of nine families with the Carney–Stratakis dyad of 'paraganglioma and gastric stromal sarcoma' (Figures 1 and 2) from the United States, France and Italy. None had mutations of the *PDGFRA* or *KIT* genes (data not shown); however, seven probands had a mutation or a deletion in one of the three succinate

Table 2 Primers used in *SDHB* deletion analysis (case CTRS.20)^a

Gene	Amplicon	Primers
<i>GAPDH</i>	Exon 8	F: GTCAGTGGTGGACCTGACCT R: TCGCTGTTGAAGTCAGAGGA
	<i>SDHB</i>	F: GAAGCCGCCTCCCACCTG R: GCTTTCCTGACTTTTCCC
<i>SDHB</i>	Exon 2	F: TCTGTTGTGCCAGCAAATG R: GCCTCCAAGGATGTGAAAA
	Exon 3	F: ACATCCAGGTGTCTCCGATT R: CTATCAGCTTTGGCCAGC
	Exon 4	F: GTCAGTGCTGTCCCCTGAT R: TGCAAATAAAAAACAAACCA
	Exon 5	F: GCTGAGGTGATGATGGAATCT R: CCACACTCCTGGCAATCATC
	Exon 6	F: ATGCACTGACCCCAAAGGTA R: CAGCAATCTATTGTCTCTTG
	Exon 7	F: CTTTCCTCTGCACTCCCAGA R: TTGTGAGCACATGCTACTTC
	Exon 8	F: GGAAGGAGTTTACCCCAAGA R: TGCTGTATTTCATGGAAAACCAA

F, forward; R, reverse.

^aSee Figure 7.

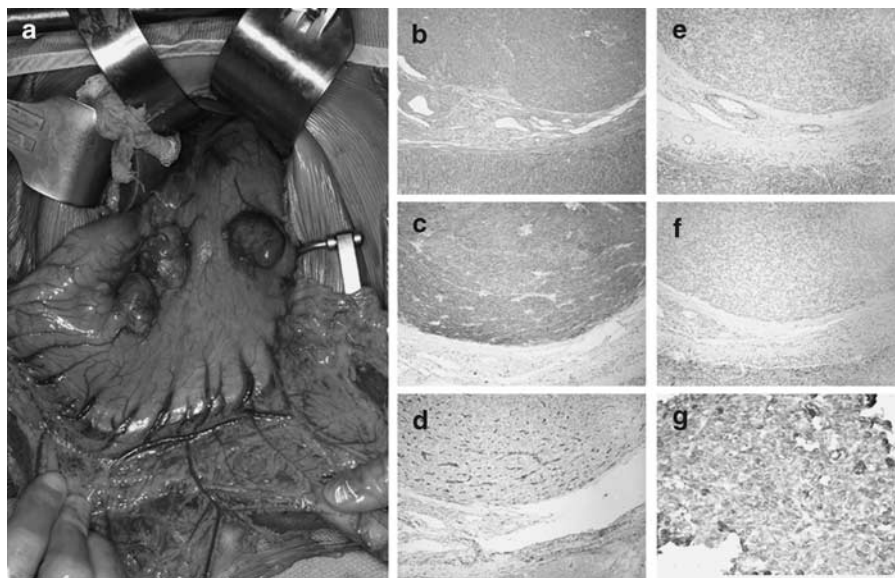


Figure 1 (a) Multiple tumors protrude from the anterior wall of stomach of patient CTRS35; two show surface bosselation. (b) Hematoxylin and eosin staining of one of the stomach GISTs from the CTRS35 patient; staining with (c) cKIT, (d) CD-34, (e) actin, (f) desmin and (g) vimentin.

dehydrogenase subunit-encoding genes (*SDHB*, *SDHC* or *SDHD*). The genomic DNA mutations have been published elsewhere.⁹ In this article, we report the clinical information of the patients and study the effects of these mutations on the transcribed message and/or tumors. There were no mutations in the coding sequence of the *SDHA* gene; a number of *SDHA* sequence variants were identified in the study patients but they were present in similar frequency in the control DNA (data not shown).

There were mutations in the *SDHB* gene in three families: in the first family, a 37-year-old male (CTRS35) had melena resulting from ulceration of a stomach GIST (Figure 1). During workup for metastatic disease, a non-functioning periaortic paraganglioma was found (Figure 2). The patient carried a relatively frequent germline mutation in intron 1 of the *SDHB* gene (IVS1+1 G>T or c.72+1G>T);^{5,9,14} cDNA analysis from his white blood cells revealed the heterozygous presence of an aberrant transcript that, when sequenced, indicated that the first part of intron 1 was transcribed (Figure 3) with the frameshift resulting in a stop codon in the middle of exon 2 and predicting a significantly truncated protein. The patient's GIST contained the mutant *SDHB* sequence only (Supplementary Figure 1), indicating loss of the normal *SDHB* allele. The patient's mother was operated for a pheochromocytoma at the age of 57; her DNA was not available.

In the second family (CTR02), monozygotic twin brothers were diagnosed with the Carney–Stratakis syndrome;¹⁷ one was operated at 12 years of age for a non-functioning paraganglioma of the organ of Zuckerkandl, and the other for a stomach GIST at age 13 years. Monozygosity was confirmed by polymorphic micro-

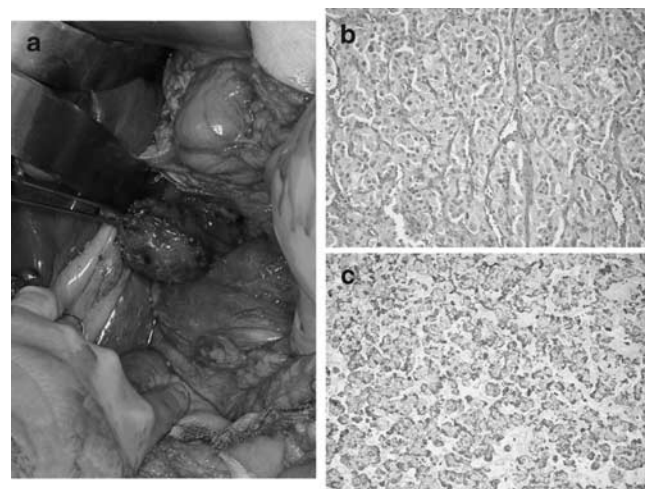


Figure 2 (a) Retroperitoneal paraganglioma with dilated veins on its surface from patient CTRS35; (b) hematoxylin and eosin staining of the paraganglioma excised from patient CTRS35; and (c) staining with the neuroendocrine marker chromogranin A.

satellite markers: the twins shared identical haplotypes (Table 3). Both carried a rare germline splice site mutation (IVS4+1G>C or c.423+1G>C) in intron 4 of the *SDHB* gene.⁴ Analysis of the cDNA from lymphocytes of one of the brothers showed that the last 18 codons of exon 4 were spliced out (Figure 4), predicting a shorter *SDHB* protein. This mutation was also present in the patients' mother and a sister; both had negative examinations for GIST and paraganglioma.

In the third kindred (B8893/T8231), the proband, now 50 years of age, had a para-aortic paraganglioma and a

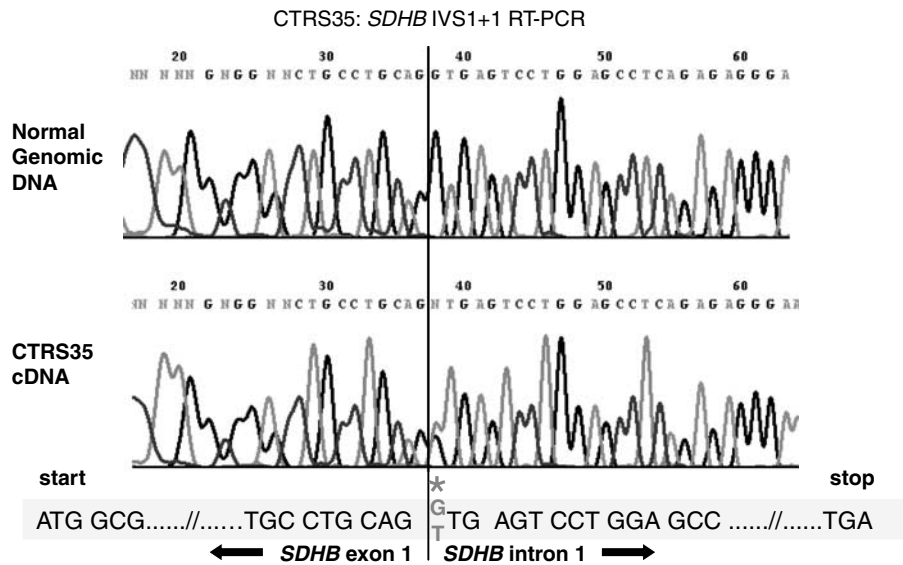


Figure 3 cDNA studies (RT-PCR) of the CTRS35 *SDHB* IVS1 + 1 mutation (*): it caused intron 1 to be transcribed, resulting in a predicted truncated protein with a stop codon coded by a downstream sequence (318 bp) of intron 1.

Table 3 Genotyping of identical twin brothers (family CTR02, individuals PGL146001 and PGL146002)^a

	PGL146001	PGL 146002
D1S1595	202/208	202/208
D1S2624	286/286	286/286
D11S934	178/180	178/180
D11S968	142/146	142/146
D14S264	220/228	220/228
D14S283	134/142	134/142
D14S990	140/154	140/154

^aGenotyping of seven fluorescent markers located in chromosomes 1, 11 and 14 in germline DNA. Following amplification, the amplicons were subjected to electrophoresis and analyzed with an ABI 3700 instrument. The data are given in base pairs.

stomach GIST. At age 26 years, she had severe hypertension and increased urinary content of catecholamines and vanillylmandelic acid. A left nephrectomy and adrenalectomy was performed. The resected specimen included three extra-adrenal paragangliomas. The patient had a novel germline 45_46insCC mutation in exon 1 of the *SDHB* gene that caused a frameshift and premature termination at codon 76 of the predicted *SDHB* protein. Allelic marker analysis suggested loss of the *SDHB* wild-type allele in both the GIST and the paraganglioma from the proband (Figure 5). The proband inherited the mutation from her father who died at the age of 75 years from a poorly differentiated lung adenocarcinoma associated with lung and pleura fibrosis and silicosis: the *SDHB* mutation was present in the father's normal lung tissue (data not shown).

There were two mutations in the *SDHC* and one in the *SDHD* genes. In the fourth family, the proband was a 29-year-old woman (PGL214) who was operated for a pancreatic, non-functional paraganglioma and, a year later, for a large retroperitoneal GIST. A novel, germline nonsense mutation in the *SDHC* gene (c.43C>T; p. Arg15X) was found.⁹ The activity of the succinate dehydrogenase-dependent SCCR in the GIST of the proband was significantly decreased with normal COX and QCCR activities;⁹ there was loss of the wild-type *SDHC* sequence (data not shown), demonstrating (for the first time in a GIST and, indeed, in any tumor) that ablation of *SDHC* can cause a severe reduction of succinate dehydrogenase activity.

In the fifth family, the proband (CTRS8), a 20-year-old female, had a gastric GIST and a non-functioning, abdominal, extra-adrenal paraganglioma; she had a rare germline intronic mutation in the *SDHC* gene (IVS5 + 1G>A or c.405 + 1G>A).⁶ cDNA analysis revealed the transcriptional effect of this splice-site substitution: the mutant allele resulted in a sequence in which exon 5 was spliced out (Figure 6), resulting in a frameshift and a stop codon in the 3' untranslated region of the gene. More than 75% of the patient's GIST cells showed allelic losses of the *SDHC* gene locus,⁹ although the normal sequence was still detectable in the chromatograms (data not shown). The patient inherited the mutation from her apparently clinically healthy 50-year-old mother.

In the sixth family, the proband (SDH9/04:MB00205) was a 19-year-old male patient who presented with melena from a stomach GIST. At age 21, the patient had a right carotid body tumor and a left adrenal pheochromocytoma;

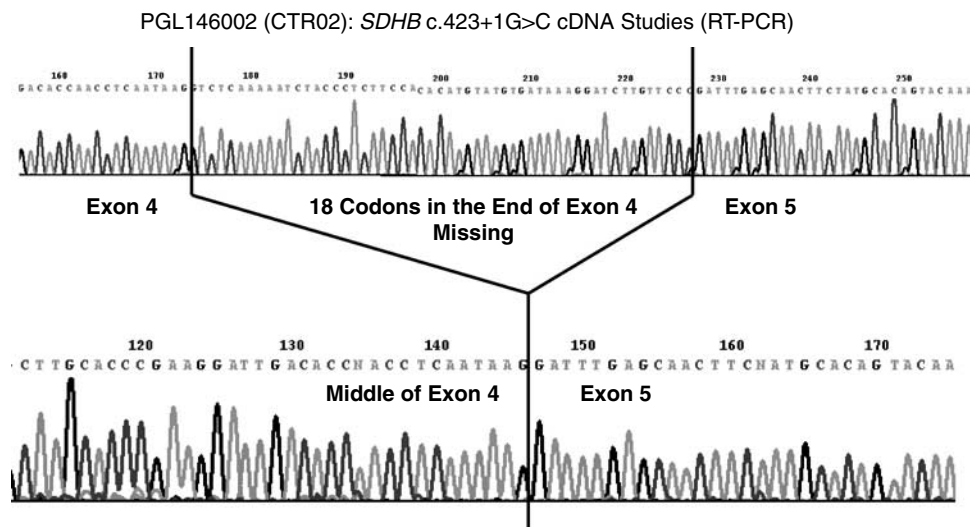
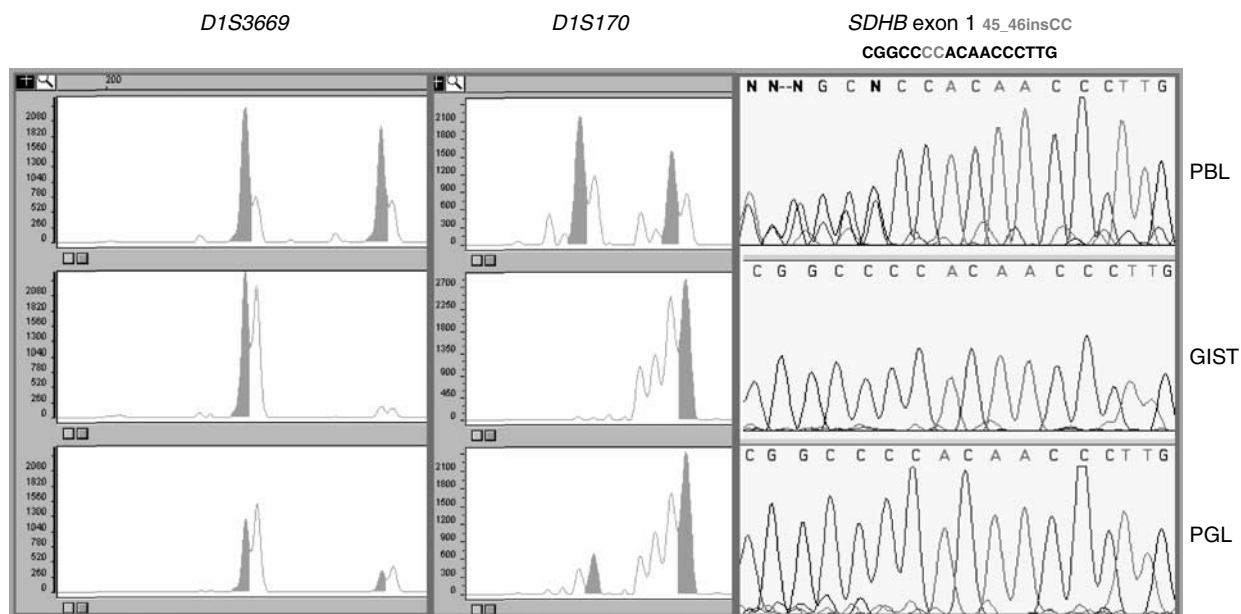


Figure 4 cDNA studies (RT-PCR) of the PGL146002 (family CTR02) *SDHB* c.423+1G>C mutation; the predicted protein was shorter but remained in frame.



PBL= peripheral blood lymphocytes; GIST=gastrointestinal tumor;
PGL=paraganglioma

Figure 5 Loss-of-heterozygosity analysis revealed loss of the *SDHB* normal allele (the haplotypes segregating with the non-mutant allele were confirmed by analysis of multiple family members) in both a GIST and a para-aortic paraganglioma from patient B8893/T8231.

a left glomus jugular tumor was excised a year later. At age 32 he presented with metastatic paraganglioma. Sequencing of germline DNA for the genes encoding succinate dehydrogenase subunits showed a novel germline deletion of a single base at nucleotide 57 of the *SDHD* gene (c.57delG).⁹ The mutation resulted in shift in the predicted translation frame of the encoded mRNA from codon 20 to a premature stop codon at position 85. There was no tumor

DNA from this patient available; although his lesions were reported to be metastatic, we were not able to prove that genetically.

Because coding sequence mutations were not identified by sequencing the *SDHB*, *SDHC* and *SDHD* genes in the remaining three families, their DNA was also searched for deletions of the respective genes and/or their loci. This analysis revealed a large germline *SDHB* gene deletion

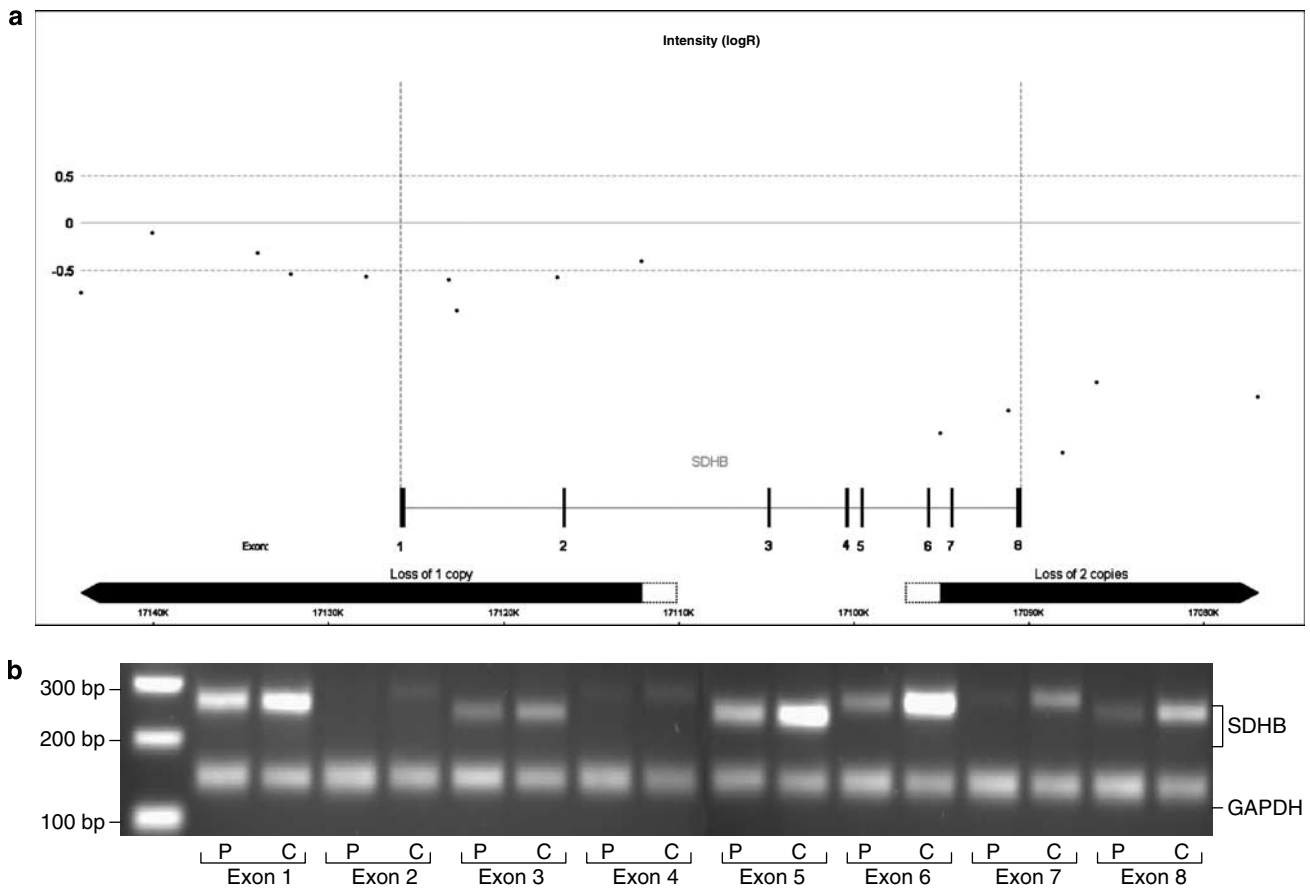


Figure 7 (a) SNP intensity in the *SDHB* region. The value is a normalized ratio in a log2 scale (–0.5 corresponds to loss deletion of one allele). (b) Semi-quantitative duplex PCR of *SDHB* exons compared to *GAPDH* exon 8.

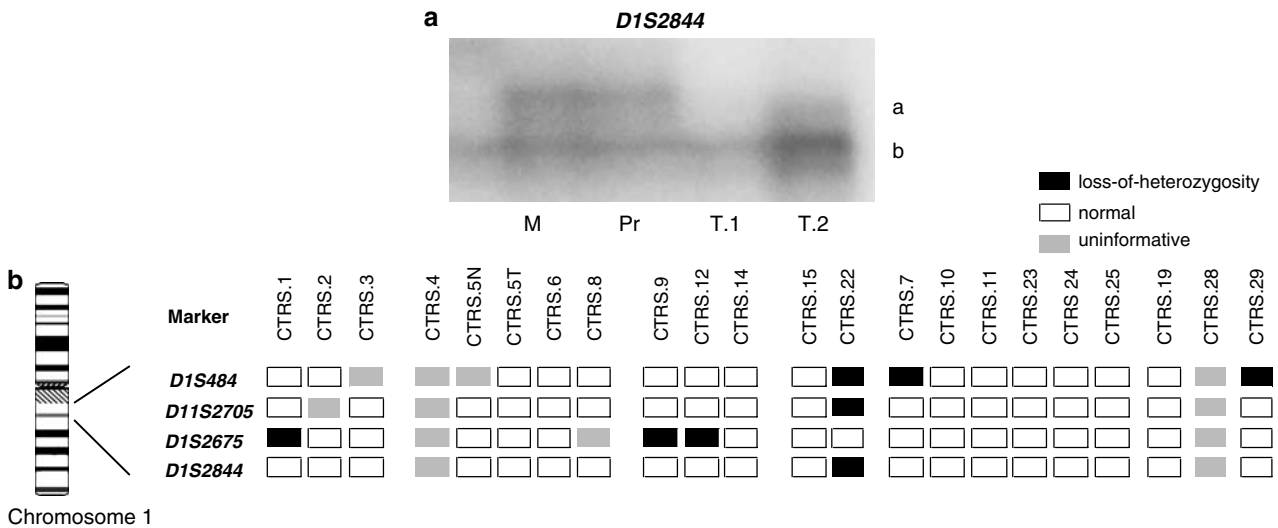


Figure 8 (a) Loss of the normal allele of the chromosome 1 *SDHC* locus in a GIST from CTRS8; the mother and the patient, who are both carriers of the *SDHC* IVS5 + 1G>A mutation are heterozygotes for the *D1S844* a and b alleles, whereas the two tumor samples have retained the b allele. (b) *SDHC* locus losses among 22 tumors with no *SDHC* mutations from patients with Carney triad and related conditions: 27% (6/22) of the tumors show at least one allelic marker loss in the vicinity of the *SDHC* gene.

Mutations in *KIT* and *PDGFRA*, either somatic or germline, are mutually exclusive events which result in the activation of common signaling pathways including the PI3K/AKT anti-apoptotic, JAK/STAT3 transcriptional and Ras/MAPK mitogenic pathways that respond to STI571 and its analogs.^{10,21,23} The existence of GISTs that lack detectable somatic mutations in either *KIT* or *PDGFRA* suggests that a different signaling pathway of tumorigenesis may be involved in the pathogenesis of these neoplasms.

Here we studied the identified germline loss-of-function mutations in the *SDHB*, *SDHC* and *SDHD* genes⁹ in patients having a recently described familial syndrome known as the dyad of ‘paranglioma and gastric stromal sarcoma’,² referred to as the ‘Carney–Stratakis syndrome’.³ The patients presented at a young age (median age 19 years; Table 1). Their tumors displayed losses of the normal allele of the succinate dehydrogenase subunit genes and they (or their relatives) also had paragangliomas, often at multiple sites,^{2,7,9,17} which prompted us to investigate the sequence of the succinate dehydrogenase subunit genes in germline DNA from these patients.

Three of the mutations we identified had been described before in sporadic or familial pheochromocytomas or extra-adrenal paragangliomas^{4–6,8,14} (Table 4). A I127S missense mutation of the *SDHB* gene in a patient with a paraganglioma, who had a family history of paragangliomas, pheochromocytoma and whose maternal grandfather reportedly had a GIST, was also recently described.⁷ A review of the reported *SDHB* genetic changes and the ones described here does not reveal an obvious genotype–phenotype correlation

(Table 4); however, *SDHC* mutations are generally rare and have only been found in head and neck paragangliomas.⁶ Our two patients with *SDHC* mutations and the dyad (PGL214 and CTRS8) are the first cases with abdominal paragangliomas caused by mutations of this gene.

In one case, we had twins presenting one with a GIST and another with a paraganglioma (family CTR02, extensively described in Baccon-Gibod *et al*¹⁷); although technically for each one of these two patients the diagnosis of the dyad cannot be given, the identification of a common genetic defect supports the probable diagnosis of this syndrome. This family also shows the clinical heterogeneity among our patients: in CTR02, two older patients (the mother and an older sibling) are carriers and unaffected; and from the two affected carriers, one twin had a paraganglioma and the other a GIST.

The absence of *KIT* or *PDGFRA* somatic mutations and occurrence of loss of one of the succinate dehydrogenase subunits in GISTs from patients with the dyad, suggests that a deficient mitochondrial tumor suppressor gene pathway is responsible for tumor formation and not constitutively active tyrosine kinases. Succinate dehydrogenase is thus potentially a new molecular target for STI571-unresponsive GISTs. Indeed, gene expression studies in sporadic GISTs without *KIT* or *PDGFRA* mutations revealed upregulation of genes linked to the mitochondrial tumor suppressor gene pathway including VEGF,²⁴ a known target of the HIF1 transcription factor.²⁵ As succinate dehydrogenase-dependent tumorigenesis has been associated with an increase in HIF1 α nuclear pro-

Table 4 Previously reported succinate dehydrogenase subunit gene mutations: literature reports (January 2007)

Gene	Mutation	Sequence	Cases and phenotype	Reference
<i>SDHB</i>	IVS1+1G>T	c.72+1G>T (same)	Abdominal PGL; no FHx (1 case) Abdominal and thoracic PGLs; sporadic and familial; (4 cases: F-44, F-45, F-55 and F-60) Abdominal PGLs (2 cases) sporadic; one malignant	Elston <i>et al</i> , <i>Int Med J</i> 2006; 36: 129 (this is case F-44 in Benn <i>et al</i> , see below) Benn <i>et al</i> ¹⁴ Brouwers <i>et al</i> ⁵
<i>SDHB</i>	IVS4+1G>C	c.423+1G>C (same) c.423+1G>A (different substitution)	PGLs (1 case; no other details) PGLs (4 cases; no other details) Neck PGL (1 case)	Amar <i>et al</i> ⁴ Amar <i>et al</i> ⁴ Bayley <i>et al</i> , <i>BMC Med Genet</i> 2006; 7 doi:10.1186/1471-2350-7-1
<i>SDHB</i>	Gene deletion	Variable size ^a Variable size ^a	Neck PGL (1 case) Neck, abdominal PGL (1 family; BRZ01)	Cascón <i>et al</i> , <i>Genes Chrom Cancer</i> 2006; 45: 213 McWhinney <i>et al</i> ¹⁶
<i>SDHC</i>	IVS5+1G>A	c.405+1G>A	Neck PGL (2 cases, #5 and #7) Neck PGL (1 case; same as #7, above)	Schiavi <i>et al</i> ⁶ Niemann <i>et al</i> , <i>Hum Genet</i> 2003; 113: 92

PGL, paraganglioma.

^aThe three *SDHB* gene deletions (the two described so far and the one in this article) are of variable size.

tein,²⁶ it is not unreasonable to speculate that the development of non-KIT and non-PDGFR α -associated GISTs may be associated with abnormal regulation of the hypoxic or pseudo-hypoxic pathway.

In conclusion, familial GISTs may be caused by mutations of the succinate dehydrogenase subunit genes *SDHB*, *SDHC* and *SDHD*, and abdominal paragangliomas associated with GISTs may be caused uniquely by *SDHC* mutations. Although we do not recommend at this point that all patients with succinate dehydrogenase subunit mutations are screened for GISTs by imaging studies, we do suggest that a careful medical and family history regarding gastrointestinal symptoms and/or tumors should be recorded in every patient with such germline genetic defects. The present study impacts genetic counseling of patients with GISTs or paragangliomas, has implications on the understanding of GIST formation and/or progression, and may lead to new therapies for these tumors.

Acknowledgements

This work was supported by NIH intramural project Z01-HD-000642-04 to Dr CA Stratakis; and, in part, by a Bench-to-Bedside Award from the Office of Rare Disorders (ORD) and the National Institute of Child Health and Human Development (NICHD), NIH, to Drs Stratakis and Eng for the study of the 'Genetics of inherited paragangliomas and gastric stromal tumors associated with adrenal and other tumors' and by a grant to Anne-Paule Gimenez-Roqueplo by the GIS-Institut des Maladies Rares for the PGL.NET network. The work of B Pasini and B Ferrando has been supported by Compagnia di San Paolo (Turin) and AIRC (Associazione Italiana Ricerca sul Cancro). Dr C Eng is a recipient of the Doris Duke Distinguished Clinical Scientist Award. The authors are grateful to Dr M Beghini, Dr A Aiello and M Gobbo for technical assistance, and to Prof M Aglietta and Prof M Papotti for reviewing part of the the clinical and pathological data.

References

- Rubin BP: Gastrointestinal stromal tumours: an update. *Histopathology* 2006; **48**: 83–96.
- Carney JA, Stratakis CA: Familial paraganglioma and gastric stromal sarcoma: a new syndrome distinct from the Carney triad. *Am J Med Genet* 2002; **108**: 132–139.
- Daum O, Vanecek T, Sima R, Michal M: Gastrointestinal stromal tumor: update. *Klinicka Onkologie* 2006; **19**: 203–211.
- Amar L, Bertherat J, Baudin E *et al*: Genetic testing in pheochromocytoma or functional paraganglioma. *J Clin Oncol* 2005; **23**: 8812–8818.
- Brouwers FM, Eisenhofer G, Tao JJ *et al*: High frequency of *SDHB* germline mutations in patients with malignant catecholamine-producing paragangliomas: implications for genetic testing. *J Clin Endocrinol Metab* 2006; **91**: 4505–4509.
- Schiavi F, Boedeker CC, Bausch B *et al*: Predictors and prevalence of paraganglioma syndrome associated with mutations of the *SDHC* gene. *JAMA* 2005; **294**: 2057–2063.
- Bolland M, Benn D, Croxson M *et al*: Gastrointestinal stromal tumour in succinate dehydrogenase subunit B mutation-associated familial pheochromocytoma/paraganglioma. *ANZ J Surg* 2006; **76**: 763–764.
- Neumann HP, Pawlu C, Peczkowska M *et al*: European-American paraganglioma study group. Distinct clinical features of paraganglioma syndromes associated with *SDHB* and *SDHD* gene mutations. *JAMA* 2004; **292**: 943–951.
- Passini B, McWhinney SR, Bei T *et al*: Germline mutations of the genes encoding succinate dehydrogenase subunits (*SDHB*, *SDHC*, and *SDHD*) cause a familial form of gastrointestinal stromal tumors. *N Engl J Med* (in press).
- Hirota S, Isozaki K, Moriyama Y *et al*: Gain-of-function mutations of c-kit gene in gastrointestinal stromal tumors. *Science* 1998; **279**: 577–580.
- Chompret A, Kannengiesser C, Barrois M *et al*: *PDGFRA* germline mutation in a family with multiple cases of gastrointestinal stromal tumor. *Gastroenterology* 2004; **126**: 318–321.
- de Raedt T, Cools J, Debiec-Rychter M *et al*: Intestinal neurofibromatosis is a subtype of familial GIST and results from a dominant activating mutation in *PDGFRA*. *Gastroenterology* 2006; **131**: 1907–1912.
- Bertherat J, Groussin L, Sandrini F *et al*: Molecular and functional analysis of *PRKARIA* and its locus (17q22-24) in sporadic adrenocortical tumors: 17q losses, somatic mutations, and protein kinase A expression and activity. *Cancer Res* 2003; **63**: 5308–5319.
- Benn DE, Gimenez-Roqueplo AP, Reilly JR *et al*: Clinical presentation and penetrance of pheochromocytoma/paraganglioma syndromes. *J Clin Endocrinol Metab* 2006; **91**: 827–836.
- Bénit P, Goncalves S, Philippe Dassa E, Brière JJ, Martin G, Rustin P: A three-shot assay for the measurement of the five respiratory chain complexes in minute amount of biological samples. *Clin Chim Acta* 2006; **374**: 81–86.
- McWhinney SR, Pilarski RT, Forrester SR *et al*: Large germline deletions of mitochondrial complex II subunits *SDHB* and *SDHD* in hereditary paraganglioma 1. *J Clin Endocrinol Metab* 2004; **89**: 5694–5699.
- Boccon-Gibod L, Boman F, Boudjema S, Fabre M, Leverger G, Carney AJ: Separate occurrence of extra-adrenal paraganglioma and gastrointestinal stromal tumors in monozygotic twins: probable familial Carney syndrome. *Pediatr Dev Pathol* 2004; **7**: 380–384.
- Parfitt JR, Streutker CJ, Riddell RH, Driman DK: Gastrointestinal stromal tumors: a contemporary review. *Pathol Res Pract* 2006; **202**: 837–847.
- Kindblom LG, Remotti HE, Aldenborg F, Meis-Kindblom JM: Gastrointestinal pacemaker cell tumor (GIPACT): gastrointestinal stromal tumors show phenotypic characteristics of the interstitial cells of Cajal. *Am J Pathol* 1998; **152**: 1259–1269.
- Miettinen M, El-Rifai W, HL Sobin L, Lasota J: Evaluation of malignancy and prognosis of gastrointestinal stromal tumors: a review. *Hum Pathol* 2002; **33**: 478–483.
- Heinrich MC, Corless CL, Duensing A *et al*: *PDGFRA* activating mutations in gastrointestinal stromal tumors. *Science* 2003; **299**: 708–710.
- Kang HJ, Nam SW, Kim H *et al*: Correlation of KIT and platelet-derived growth factor receptor alpha mutations with gene activation and expression profiles in gastrointestinal stromal tumors. *Oncogene* 2005; **24**: 1066–1074.
- Antonescu CR: Gastrointestinal stromal tumor (GIST) pathogenesis, familial GIST, and animal models. *Semin Diagn Pathol* 2006; **23**: 63–69.
- Schmahl J, Raymond CS, Soriano P: PDGF signaling specificity is mediated through multiple immediate early genes. *Nat Genet* 2007; **39**: 52–60.
- Selak MA, Armour SM, MacKenzie ED *et al*: Succinate links TCA cycle dysfunction to oncogenesis by inhibiting HIF- α prolyl hydroxylase. *Cancer Cell* 2005; **7**: 77–85.
- Briere JJ, Favier J, Benit P *et al*: Mitochondrial succinate is instrumental for HIF1 α nuclear translocation in *SDHA*-mutant fibroblasts under normoxic conditions. *Hum Mol Genet* 2005; **14**: 3263–3269.

Supplementary Information accompanies the paper on European Journal of Human Genetics website (<http://www.nature.com/ejhg>)